Multidisciplinary Cancer Investigation Original Article

April 2023, Volume 7, Issue 2

Breast Elastography of Invasive Lobular Carcinomas

Lynda Aoudia[1,2*], Salah Eddine Bendib[1,3]

[1] Department of Medical Imaging, Faculty of Medicine, University Algiers 1, Algiers, Algeria

[2] Department of Radiology and Medical Imaging, Ben-Aknoun Hospital, Algiers, Algeria

[3] Department of Radiology and Medical Imaging, Pierre and Marie Curie Center, Algiers, Algeria

**Corresponding author: Lynda Aoudia, Department of Radiology and Medical Imaging, Ben-Aknoun Hospital, Chemin des Deux Bassins, Ben Aknoun 16306, Algiers, Algeria. Tel: +213772104747; Fax: + 213 23384145. E-mail: aoudia_lynda@hotmail.com*

DOI: 10.30699/mci.7.2.648-1

Submitted: 6 January 2023

Revised: 23 February 2023

Accepted: 24 March 2023

e-Published: 2 April 2023

Keywords:
Breast
Elastography
Ultrasound
Mass
Lobular Carcinoma

Introduction: The study attempted to investigate the contribution of elastography in the diagnosis and assessment of the extent of Invasive Lobular Carcinomas (ILCs) compared to Invasive Carcinomas of no Special Type (ICNST).

Methods: The current retrospective study included 85 female patients (mean age: 55 years) with invasive breast carcinoma. Ultrasound B mode and strain elastography were performed for each mass. Qualitative criteria (elasticity score) and quantitative criteria (strain and length ratio) of elastography were studied. Histopathological examination was considered the gold standard for final diagnosis.

Results: Of 85 invasive carcinomas, there were 30 ILCs and 55 ICNST. The strain ratio of ILCs was higher than ICNST ($P<0.05$). The mean length ratio of ILCs was significantly higher than ICNST ($P<0.0001$). The lesions were mostly scored 5 in both histological types without significant difference ($P=0.13$).

Conclusion: Invasive lobular carcinoma poses a problem in detecting and extending lesions to conventional imaging. Breast ultrasound elastography can help diagnose and evaluation of the extent of invasive lobular carcinoma.

© 2023. Multidisciplinary Cancer Investigation

INTRODUCTION

Invasive Lobular Carcinomas (ILCs) is the second most common histological type of invasive breast cancer after Invasive Carcinomas of no Special Type (ICNST), formerly known as Invasive Ductal Carcinoma (IDC) [1, 2]. It accounts for approximately 10-15% of all invasive breast cancers [1-3]. The incidence of ILC is increasing significantly, from 9.5% in 1987 to 15.6 % in 1999 in the United States [4]. Several hypotheses have been attributed to this increase, such as the use of menopausal hormone therapy [5, 6]. The detection of ILC in conventional imaging is manifestly difficult. It may have particular and sometimes subtle presentations [7, 8]. It represents the first etiology of false negatives and interval cancers [9-11]. The second problem in the ILC is the evaluation of its size. It is challenging to appreciate the extent of lesions in mammography and B-mode ultrasound, but preoperative MRI is usually indicated [11-15]. Elastography is an ultrasound technique used to evaluate the hardness of tissues, qualitatively represented by the elasticity score and semi-quantitative by the strain and length ratio. Many studies reported that the combination ultrasound-elastography increases the diagnostic performance to differentiate between benign and malignant breast masses [16-23]. It would probably highly effective to integrate elastography in the imaging assessment of ILCs to improve

the diagnostic performance of ultrasound. This study attempted to investigate the contribution of elastography in the diagnosis and evaluation of the extent of ILCs compared to ICNSTs.

METHODS

Between January 2016 and December 2020, we retrospectively analyzed conventional ultrasound and elastography images of all patients with invasive carcinoma stored in our department's computer system. One hundred and fifty-one malignant masses were studied, of which 66 lesions were excluded from the study for different reasons: 20 lesions without postoperative histological conformation, 20 lesions with incomplete conventional ultrasound and/or elastography data, 15 lesions in patients receiving neoadjuvant hormonal therapy or neoadjuvant chemotherapy, and 11 miscellaneous invasive carcinoma lesions (mixed lobular carcinomas (n=4), micro-papillary carcinomas (n=2), papillary carcinoma (n=1), cribriform carcinoma (n=1), colloid carcinoma (n=1), apocrine carcinoma(n=1), and neuroendocrine carcinoma (n=1). A total of 85 masses, 30 ILC lesions and 55 ICNST lesions, in 81 patients were included in our study (Figure 1). The final diagnosis was based on the histopathology of the surgical specimen.

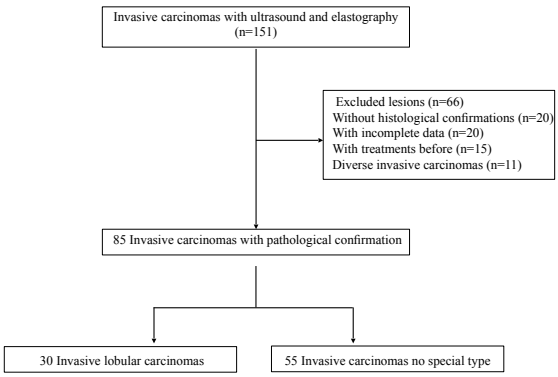

Figure 1: Flowchart of the Selection of Invasive Carcinomas

B-Mode Ultrasound and Elastography Examinations

All patients with ultrasound visible breast mass were examined using ultrasound machine systems equipped with linear-array high-frequency 14-6 MHz transducer (Hi-Vision system, Hitachi Medical). All B-mode ultrasound and elastography images were performed and analyzed by a radiologist with 17 years of breast imaging experience. For each mass, we specified the size in millimeters and classified according to the American. College of Radiology Breast Imaging Reporting and Data System (BI-RADS) atlas [24]. BI-RADS 3 (probability of malignancy<2%) was assigned to the lesion with an oval shape, circumscribed margin, isoechoic, and parallel orientation to the skin. BI-RADS categories 4a, 4b, 4c, or 5 were assigned according to the number of suspicious characteristics [22]. Color elastography images were scored according to the scale suggested by Itoh et al., [16]. A score 1 indicated the lesion was entirely colored green, score 2 showed the lesion had a mosaic pattern of green and blue, score 3 showed the central part of the lesion was blue and the peripheral part was green, score 4 indicated the lesion was entirely colored blue, and score 5 showed the lesion and adjacent tissue were entirely blue. Lesions scored 1, 2, and 3 were categorized as benign, and those scored 4 and 5 were categorized as malignant. In the semi-quantitative analysis of the elastography images, the strain indices of the lesions were calculated by strain ratio (FLR) and length ratio. The strain ratio was the ratio of two Regions of Interest (ROI) drawn on the color elastography images, the first ROI in the lesion (L) and the second ROI in subcutaneous fat (F). The length ratio was calculated according to the following formula: the length of the lesion on the elastography image divided by the length of the lesion on the B-mode ultrasound. The histological diagnosis of breast carcinoma was established initially by percutaneous micro biopsy, and then confirmed after surgery. Surgical specimens were processed for tumor size and histological grade of tumor.

Statistical Analysis

Patient age, lesion size, B-Mode ultrasound characteristics (US B-Mode), elasticity score, strain, and length ratio of ILCs and ICNSTs lesions were compared. Qualitative variables were represented by the number of cases and percentages, while quantitative variables were represented by mean±SD The statistical tests used were the Chi-square test or the Fisher's exact test to compare percentages and the Student's T-test for comparing means. Statistical analysis was performed using SPSS version 23 for Mac (SPSS, Chicago, IL, USA). P value less than 0.05 was considered to be statistically significant.

RESULTS

We evaluated in our study eighty-five breast masses, including 30 ILCs and 55 ICNSTs. The mean age of the ILC and ICNST groups was 53.47±4.41 and 55.84±13.11 years, respectively without significant difference between the two groups (P=0.222).

B-Mode Ultrasound

The mean US B-Mode size of the ICNSTs was significantly larger than the ILCs (24.73±11.12 vs 17.38±9.97, P=0.002). Other significant differences were also observed between the two groups, notably in the echogenicity and the orientation of the lesions. Masses in the ILC group were more often hyperechogenic 20/30 cases (66.67%, P<0.001). However, most ICNSTs masses were hypoechogenic (38 cases, 69.1%, P<0.001). The majority of ILCs lesions (93.33%) had an orientation parallel to the skin (P< 0.001). In contrast, most of the lesions in the ICTNS group had a non-parallel orientation (39/55, P< 0.001). There was no significant difference in the presence of posterior acoustic shadowing, 56.7% (17 of 30) ILCs, and 45.5% (25 of 55) ICNSTs (P=0.323). The lesions were mostly classified as BI-RADS 4c and 5 in both histological types without significant difference. The lesions classified BI-RADS 4c were 23.3% for ILCs and 18.2% for ICNSTs (P=0.57), and 76.7% of ICLs versus 80% of ICNSTs were classified BI-RADS 5, P=0.36 (Table 1).

Table 1: Distribution of ILCs and ICNSTs for Ultrasound and Elastography[a]

	ILC (n=30)	ICNST (n=55)	P Value
BI-RADS Category, No.(%)			0.73
4b	0	1 (1.8)	
4c	7 (23.3)	10 (17.5)	
5	23 (76.7)	44 (80.7)	
Elasticity Score, No.(%)			0.71
3	0	1 (1.8)	
4	0	3 (5.5)	
5	30 (100)	51 (92.7)	
Stain Ratio, Mean±SD	56.40±46.28	28.43±35.43	0.004
Length Ratio, Mean±SD	1.56±0.39	1.21±0.14	<0.0001

[a] Abbreviations: ICNSTS, invasive carcinomas of no special type; ILCs, invasive lobular carcinomas

Elastography

For the elasticity score, all ILC lesions and most ICNST lesions were scored 5 (30/30 of the ILCs vs. 51/55 of the ICNSTs, P=0.13). The distribution of the elasticity scores between the two histological groups is summarized in the Table 1. The mean strain ratio of the ILCs was significantly higher than that of the ICNSTs (56.4±46.28 vs. 28.43±35.43, P=0.004), so the ILCs were harder on elastography

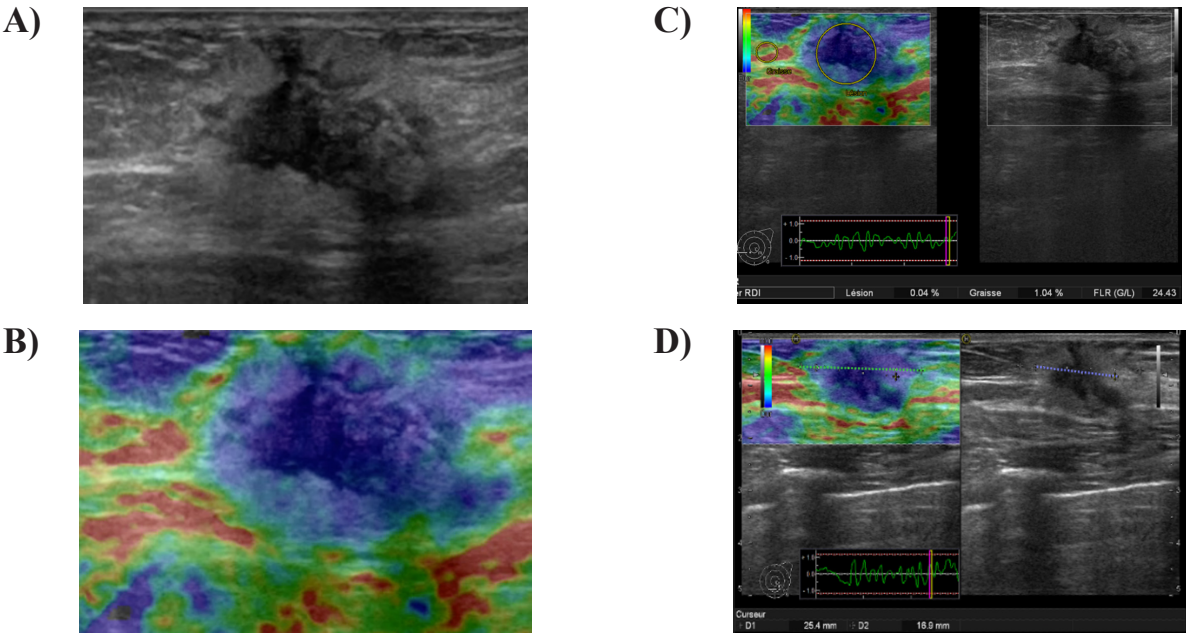

Figure 2: A 52-Year-Old Woman With a Breast Mass
A) The B-mode US image shows a mass classified as BI-RADS category 5; B) The elastography image shows an elasticity score was 5; C) a strain ratio was 24.43; and D) a length ratio equal to 1.5. Histology: ICNST.

Multidisciplinary Cancer Investigation Original Article

April 2023, Volume 7, Issue 2

Breast Elastography of Invasive Lobular Carcinomas

Lynda Aoudia[1,2*], Salah Eddine Bendib[1,3]

[1] Department of Medical Imaging, Faculty of Medicine, University Algiers 1, Algiers, Algeria

[2] Department of Radiology and Medical Imaging, Ben-Aknoun Hospital, Algiers, Algeria

[3] Department of Radiology and Medical Imaging, Pierre and Marie Curie Center, Algiers, Algeria

**Corresponding author: Lynda Aoudia, Department of Radiology and Medical Imaging, Ben-Aknoun Hospital, Chemin des Deux Bassins, Ben Aknoun 16306, Algiers, Algeria. Tel: +213772104747; Fax: + 213 23384145. E-mail: aoudia_lynda@hotmail.com*

DOI: 10.30699/mci.7.2.648-1

Submitted: 6 January 2023

Revised: 23 February 2023

Accepted: 24 March 2023

e-Published: 2 April 2023

Keywords:
Breast
Elastography
Ultrasound
Mass
Lobular Carcinoma

Introduction: The study attempted to investigate the contribution of elastography in the diagnosis and assessment of the extent of Invasive Lobular Carcinomas (ILCs) compared to Invasive Carcinomas of no Special Type (ICNST).

Methods: The current retrospective study included 85 female patients (mean age: 55 years) with invasive breast carcinoma. Ultrasound B mode and strain elastography were performed for each mass. Qualitative criteria (elasticity score) and quantitative criteria (strain and length ratio) of elastography were studied. Histopathological examination was considered the gold standard for final diagnosis.

Results: Of 85 invasive carcinomas, there were 30 ILCs and 55 ICNST. The strain ratio of ILCs was higher than ICNST ($P<0.05$). The mean length ratio of ILCs was significantly higher than ICNST ($P<0.0001$). The lesions were mostly scored 5 in both histological types without significant difference ($P=0.13$).

Conclusion: Invasive lobular carcinoma poses a problem in detecting and extending lesions to conventional imaging. Breast ultrasound elastography can help diagnose and evaluation of the extent of invasive lobular carcinoma.

© 2023. Multidisciplinary Cancer Investigation

INTRODUCTION

Invasive Lobular Carcinomas (ILCs) is the second most common histological type of invasive breast cancer after Invasive Carcinomas of no Special Type (ICNST), formerly known as Invasive Ductal Carcinoma (IDC) [1, 2]. It accounts for approximately 10-15% of all invasive breast cancers [1-3]. The incidence of ILC is increasing significantly, from 9.5% in 1987 to 15.6 % in 1999 in the United States [4]. Several hypotheses have been attributed to this increase, such as the use of menopausal hormone therapy [5, 6]. The detection of ILC in conventional imaging is manifestly difficult. It may have particular and sometimes subtle presentations [7, 8]. It represents the first etiology of false negatives and interval cancers [9-11]. The second problem in the ILC is the evaluation of its size. It is challenging to appreciate the extent of lesions in mammography and B-mode ultrasound, but preoperative MRI is usually indicated [11-15]. Elastography is an ultrasound technique used to evaluate the hardness of tissues, qualitatively represented by the elasticity score and semi-quantitative by the strain and length ratio. Many studies reported that the combination ultrasound-elastography increases the diagnostic performance to differentiate between benign and malignant breast masses [16-23]. It would probably highly effective to integrate elastography in the imaging assessment of ILCs to improve

the diagnostic performance of ultrasound. This study attempted to investigate the contribution of elastography in the diagnosis and evaluation of the extent of ILCs compared to ICNSTs.

METHODS

Between January 2016 and December 2020, we retrospectively analyzed conventional ultrasound and elastography images of all patients with invasive carcinoma stored in our department's computer system. One hundred and fifty-one malignant masses were studied, of which 66 lesions were excluded from the study for different reasons: 20 lesions without postoperative histological conformation, 20 lesions with incomplete conventional ultrasound and/or elastography data, 15 lesions in patients receiving neoadjuvant hormonal therapy or neoadjuvant chemotherapy, and 11 miscellaneous invasive carcinoma lesions (mixed lobular carcinomas (n=4), micro-papillary carcinomas (n=2), papillary carcinoma (n=1), cribriform carcinoma (n=1), colloid carcinoma (n=1), apocrine carcinoma(n=1), and neuroendocrine carcinoma (n=1). A total of 85 masses, 30 ILC lesions and 55 ICNST lesions, in 81 patients were included in our study (Figure 1). The final diagnosis was based on the histopathology of the surgical specimen.

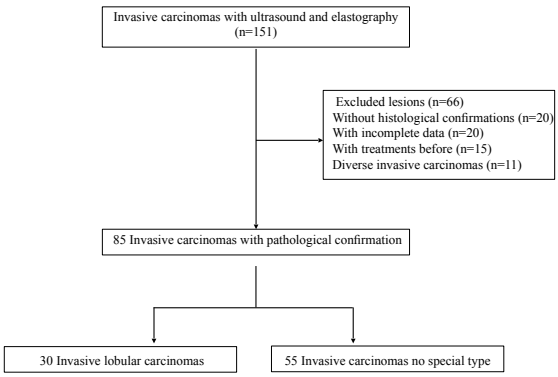

Figure 1: Flowchart of the Selection of Invasive Carcinomas

B-Mode Ultrasound and Elastography Examinations

All patients with ultrasound visible breast mass were examined using ultrasound machine systems equipped with linear-array high-frequency 14-6 MHz transducer (Hi-Vision system, Hitachi Medical). All B-mode ultrasound and elastography images were performed and analyzed by a radiologist with 17 years of breast imaging experience. For each mass, we specified the size in millimeters and classified according to the American. College of Radiology Breast Imaging Reporting and Data System (BI-RADS) atlas [24]. BI-RADS 3 (probability of malignancy<2%) was assigned to the lesion with an oval shape, circumscribed margin, isoechoic, and parallel orientation to the skin. BI-RADS categories 4a, 4b, 4c, or 5 were assigned according to the number of suspicious characteristics [22]. Color elastography images were scored according to the scale suggested by Itoh et al., [16]. A score 1 indicated the lesion was entirely colored green, score 2 showed the lesion had a mosaic pattern of green and blue, score 3 showed the central part of the lesion was blue and the peripheral part was green, score 4 indicated the lesion was entirely colored blue, and score 5 showed the lesion and adjacent tissue were entirely blue. Lesions scored 1, 2, and 3 were categorized as benign, and those scored 4 and 5 were categorized as malignant. In the semi-quantitative analysis of the elastography images, the strain indices of the lesions were calculated by strain ratio (FLR) and length ratio. The strain ratio was the ratio of two Regions of Interest (ROI) drawn on the color elastography images, the first ROI in the lesion (L) and the second ROI in subcutaneous fat (F). The length ratio was calculated according to the following formula: the length of the lesion on the elastography image divided by the length of the lesion on the B-mode ultrasound. The histological diagnosis of breast carcinoma was established initially by percutaneous micro biopsy, and then confirmed after surgery. Surgical specimens were processed for tumor size and histological grade of tumor.

Statistical Analysis

Patient age, lesion size, B-Mode ultrasound characteristics (US B-Mode), elasticity score, strain, and length ratio of ILCs and ICNSTs lesions were compared. Qualitative variables were represented by the number of cases and percentages, while quantitative variables were represented by mean±SD The statistical tests used were the Chi-square test or the Fisher's exact test to compare percentages and the Student's T-test for comparing means. Statistical analysis was performed using SPSS version 23 for Mac (SPSS, Chicago, IL, USA). P value less than 0.05 was considered to be statistically significant.

RESULTS

We evaluated in our study eighty-five breast masses, including 30 ILCs and 55 ICNSTs. The mean age of the ILC and ICNST groups was 53.47±4.41 and 55.84±13.11 years, respectively without significant difference between the two groups (P=0.222).

B-Mode Ultrasound

The mean US B-Mode size of the ICNSTs was significantly larger than the ILCs (24.73±11.12 vs 17.38±9.97, P=0.002). Other significant differences were also observed between the two groups, notably in the echogenicity and the orientation of the lesions. Masses in the ILC group were more often hyperechogenic 20/30 cases (66.67%, P<0.001). However, most ICNSTs masses were hypoechogenic (38 cases, 69.1%, P<0.001). The majority of ILCs lesions (93.33%) had an orientation parallel to the skin (P< 0.001). In contrast, most of the lesions in the ICTNS group had a non-parallel orientation (39/55, P< 0.001). There was no significant difference in the presence of posterior acoustic shadowing, 56.7% (17 of 30) ILCs, and 45.5% (25 of 55) ICNSTs (P=0.323). The lesions were mostly classified as BI-RADS 4c and 5 in both histological types without significant difference. The lesions classified BI-RADS 4c were 23.3% for ILCs and 18.2% for ICNSTs (P=0.57), and 76.7% of ICLs versus 80% of ICNSTs were classified BI-RADS 5, P=0.36 (Table 1).

Table 1: Distribution of ILCs and ICNSTs for Ultrasound and Elastography[a]

	ILC (n=30)	ICNST (n=55)	P Value
BI-RADS Category, No.(%)			0.73
4b	0	1 (1.8)	
4c	7 (23.3)	10 (17.5)	
5	23 (76.7)	44 (80.7)	
Elasticity Score, No.(%)			0.71
3	0	1 (1.8)	
4	0	3 (5.5)	
5	30 (100)	51 (92.7)	
Stain Ratio, Mean±SD	56.40±46.28	28.43±35.43	0.004
Length Ratio, Mean±SD	1.56±0.39	1.21±0.14	<0.0001

[a] Abbreviations: ICNSTS, invasive carcinomas of no special type; ILCs, invasive lobular carcinomas

Elastography

For the elasticity score, all ILC lesions and most ICNST lesions were scored 5 (30/30 of the ILCs vs. 51/55 of the ICNSTs, P=0.13). The distribution of the elasticity scores between the two histological groups is summarized in the Table 1. The mean strain ratio of the ILCs was significantly higher than that of the ICNSTs (56.4±46.28 vs. 28.43±35.43, P=0.004), so the ILCs were harder on elastography

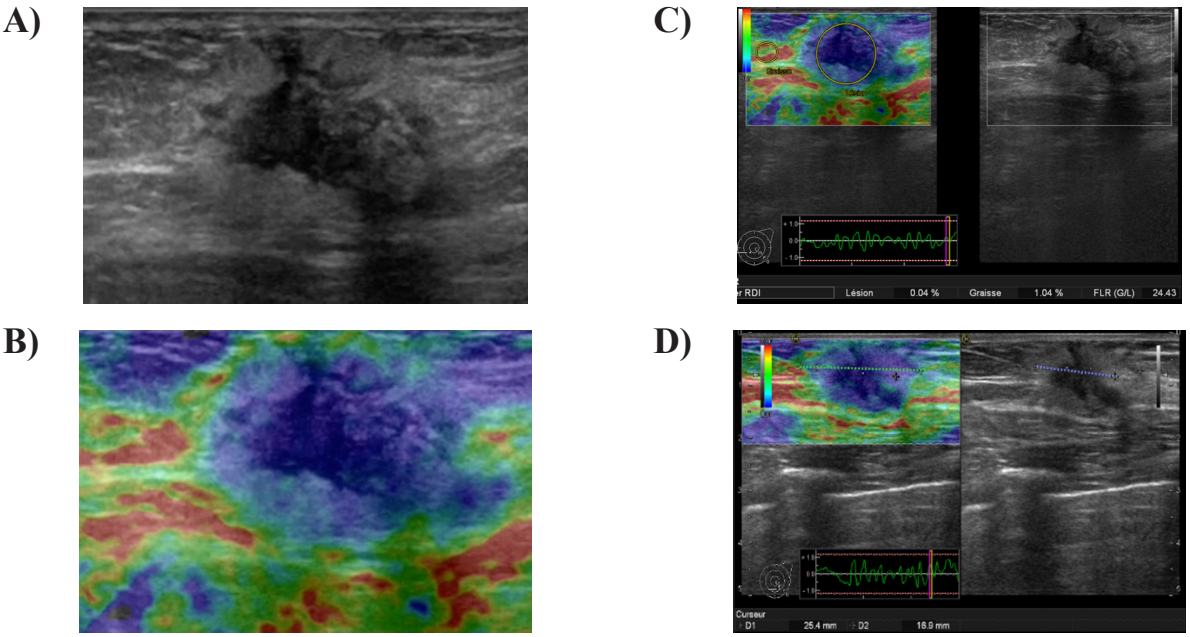

Figure 2: A 52-Year-Old Woman With a Breast Mass
A) The B-mode US image shows a mass classified as BI-RADS category 5; B) The elastography image shows an elasticity score was 5; C) a strain ratio was 24.43; and D) a length ratio equal to 1.5. Histology: ICNST.

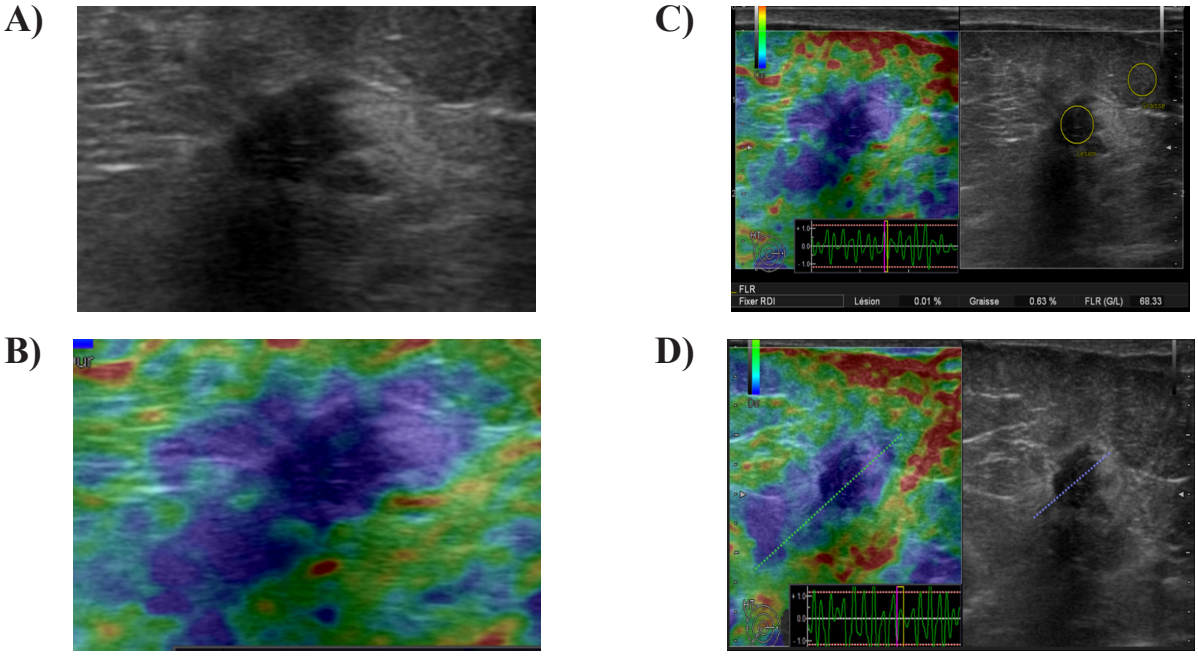

Figure 3: A 48-Year-Old Woman With a Breast Mass
A) The B-mode US image shows a mass classified as BI-RADS category 5; B) The elastography image shows an elasticity score was 5; C) a strain ratio was 68.33; and D) a length ratio equal to 2.27. Histology: ILC.

than the ICNSTs (Figures 2, 3). The average length ratio of the 30 ILCs was 1.56±0.39 and 1.21±0.14 for the 50 ICNSTs. The mean of the length ratio of ILCs was significantly higher than that of ICNSTs (P<0.001)(Figures 2, 3).

DISCUSSION

In our study, the ILCs were harder on elastography than the ICNSTs, with an average strain ratio of 56.4 ± 46.28 for ILCs and 28.43 ± 35.43 for ICNSTs, with a significant difference (P=0.004). Two studies in the literature reported that the hardness of ILCs was higher than that of ICNSTs, measured with shear-wave elastography. The first is Brkljačić study [25], the only study in the literature that compared stiffness of 75 ICNSTs and 40 ILCs and objectified that the ILCs had a higher mean elasticity than the ICNSTs, respectively 180.41±27.06 kPa vs 162.20±37.46 kPa, P<0.05. The second study is that of Evans et al., [26] evaluated the relationship between shear-wave elastographic findings and 101invasive breast cancer lesions, among the invasive cancers there were 84 ICNSTs and 7 ILCs, reported elasticity values of ILCs significantly higher than ICNSTs, 181±67 kPa vs 139±56 kPa, respectively, (P<0.0001). Several studies found no significant difference in elastography between the two histological types [26-28]. Jin Y et al., [28] assessed the relationship between stiffness and pathological factors, including histologic type, showing an average ILC strain ratio value of 66.12±25.78 versus 82.54±15.64 of an average ICNST strain ratio (P=0.13). In the Vinnicombe et al., study [29], 96.30% of ILCs and 94.32% of ICNSTs had elasticity values greater than 50 kPa (P=0.61). In total, there are various findings in the literature. In any case, elastography seems to be a particularly interesting tool to increase the sensitivity of ultrasound for the detection of ILCs, sometimes revealing zones of suspected hardness [30].

In our series, ILCs had higher length ratio values compared to ICNSTs (P<0.001). These results are consistent with the study of Grajo et al., [31] in which the length ratio of 266 invasive breast cancers, including 30 ILCs and 200 ICNSTs, was evaluated (P<0.0001) and the mean length ratio value for ILC and ICNSTs was found 1.8±0.3 and 1.5±0.07, respectively. These results also corroborate the specific histological characteristics of ILCs, consisting of small, non-cohesive tumor cells arranged in single file linear cords ("Indian files") and single cells that tend to infiltrate adjacent normal breast tissue without destroying anatomical

structures or causing an important desmoplastic stromal reaction [32]. It suggests that elastography better reflects the extent of the lesions. Considering the low sensitivity of B-mode ultrasound for detection and evaluating the extension of ILC, we suggest integrating elastography routinely during the ultrasound examination for a better detection and local extension assessment of ILCs. Elastography is a simple, fast, non-invasive diagnostic method. There were several limitations in this study. Firstly, it was a single-center retrospective study. Secondly, the sample size was relatively small. It took us five years to collect data from 30 patients with satisfactory B-mode ultrasound and elastography images in a single center.

CONCLUSION

The particular histological characteristics of the ILC make it difficult to detect conventional ultrasound compared to the ICNST. Elastography is a valuable tool for the diagnosis of ILCs by highlighting areas of suspected hardness. Elastography can also be useful to accurately assess the size of ILCs.

ACKNOWLEDGMENTS

Not applicable

CONFLICT OF INTEREST

The authors declare that they have no conflict of interest.

ETHICS APPROVAL

The present study is exclusively retrospective and do not need ethical approval according to the Algerian law for research on humans.

REFERENCES

1. Luveta J, Parks RM, Heery DM, Cheung KL, Johnston SJ. Invasive Lobular Breast Cancer as a Distinct Disease: Implications for Therapeutic Strategy. Oncol Ther. 2020;8(1):1-11. DOI: 10.1007/s40487-019-00105-0 PMID: 32700069.
2. Tan PH, Ellis I, Allison K, Brogi E, Fox SB, Lakhani S, et al. The 2019 World Health Organization classification of tumours of the breast. Histopathology. 2020;77(2):181-5. DOI: 10.1111/his.14091 PMID: 32056259.
3. Li CI, Daling JR. Changes in breast cancer incidence rates in the United States by histologic subtype and race/ethnicity, 1995 to 2004. Cancer Epidemiol Biomarkers Prev. 2007;16(12):2773-80. DOI: 10.1158/1055-9965.EPI-07-0546 PMID: 18086787.
4. Li CI, Anderson BO, Daling JR, Moe RE. Trends in incidence rates of invasive lobular and ductal breast carcinoma. JAMA. 2003;289(11):1421-4. DOI: 10.1001/jama.289.11.1421 PMID: 12636465.
5. Ravdin PM. Hormone replacement therapy and the increase in the incidence of invasive lobular cancer. Breast Dis. 2008;30:3-8. DOI: 10.3233/BD-2009-0283 PMID: 19850989.
6. Lopez JK, Bassett LW. Invasive lobular carcinoma of the breast: spectrum of mammographic, US, and MR imaging findings. Radiographics. 2009;29(1):165-76. DOI: 10.1148/rg.291085100 PMID: 19168843.
7. Chapellier C, Balu-Maestro C, Bleuse A, Ettore F, Bruneton JN. Ultrasonography of invasive lobular carcinoma of the breast: sonographic patterns and diagnostic value: report of 102 cases. Clin Imaging. 2000;24(6):333-6. DOI: 10.1016/s0899-7071(00)00234-5 PMID: 11368932.
8. Jones KN, Magut M, Henrichsen TL, Boughey JC, Reynolds C, Glazebrook KN. Pure lobular carcinoma of the breast presenting as a hyperechoic mass: incidence and imaging characteristics. AJR Am J Roentgenol. 2013;201(5):W765-9. DOI: 10.2214/AJR.12.9742 PMID: 24147507.
9. Hilleren DJ, Andersson IT, Lindholm K, Linnell FS. Invasive lobular carcinoma: mammographic findings in a 10-year experience. Radiology. 1991;178(1):149-54. DOI: 10.1148/radiology.178.1.1984294 PMID: 1984294.
10. Krecke KN, Gisvold JJ. Invasive lobular carcinoma of the breast: mammographic findings and extent of disease at diagnosis in 184 patients. AJR Am J Roentgenol. 1993;161(5):957-60. DOI: 10.2214/ajr.161.5.8273634 PMID: 8273634.
11. Le Gal M, Ollivier L, Asselain B, Meunier M, Laurent M, Vielh P, et al. Mammographic features of 455 invasive lobular carcinomas. Radiology. 1992;185(3):705-8. DOI: 10.1148/radiology.185.3.1438749 PMID: 1438749.
12. Berg WA, Gutierrez L, NessAiver MS, Carter WB, Bhargavan M, Lewis RS, et al. Diagnostic accuracy of mammography, clinical examination, US, and MR imaging in preoperative assessment of breast cancer. Radiology. 2004;233(3):830-49. DOI: 10.1148/radiol.2333031484 PMID: 15486214.
13. Wurdinger S, Kamprath S, Eschrich D, Schneider A, Kaiser WA. False-negative findings of malignant breast lesions on preoperative magnetic resonance mammography. Breast. 2001;10(2):131-9. DOI: 10.1054/brst.2000.0232 PMID: 14965573.
14. Kneeshaw PJ, Turnbull LW, Smith A, Drew PJ. Dynamic contrast enhanced magnetic resonance imaging aids the surgical management of invasive lobular breast cancer. Eur J Surg Oncol. 2003;29(1):32-7. DOI: 10.1053/ejso.2002.1391 PMID: 12559074.
15. Boetes C, Veltman J, van Die L, Bult P, Wobbes T, Barentsz JO. The role of MRI in invasive lobular carcinoma. Breast Cancer Res Treat. 2004;86(1):31-7.

DOI: 10.1023/B:BREA.0000032921.10481.dc PMID: 15218359.
16. Itoh A, Ueno E, Tohno E, Kamma H, Takahashi H, Shiina T, et al. Breast disease: clinical application of US elastography for diagnosis. Radiology. 2006;239(2):341-50. DOI: 10.1148/radiol.2391041676 PMID: 16484352.
17. Cho N, Jang M, Lyou CY, Park JS, Choi HY, Moon WK. Distinguishing benign from malignant masses at breast US: combined US elastography and color doppler US--influence on radiologist accuracy. Radiology. 2012;262(1):80-90. DOI: 10.1148/radiol.11110886 PMID: 22084209.
18. Yi A, Cho N, Chang JM, Koo HR, La Yun B, Moon WK. Sonoelastography for 1,786 non-palpable breast masses: diagnostic value in the decision to biopsy. Eur Radiol. 2012;22(5):1033-40. DOI: 10.1007/s00330-011-2341-x PMID: 22116557.
19. Lee SH, Chang JM, Kim WH, Bae MS, Seo M, Koo HR, et al. Added value of shear-wave elastography for evaluation of breast masses detected with screening US imaging. Radiology. 2014;273(1):61-9. DOI: 10.1148/radiol.14132443 PMID: 24955927.
20. Choi JS, Han BK, Ko EY, Ko ES, Shin JH, Kim GR. Additional diagnostic value of shear-wave elastography and color Doppler US for evaluation of breast non-mass lesions detected at B-mode US. Eur Radiol. 2016;26(10):3542-9. DOI: 10.1007/s00330-015-4201-6 PMID: 26787603.
21. Aoudia L, Kouchkar A, Bendib SE. [Performance of elastography and B mode ultrasound in breast mass characterization]. J Afr Imag Med. 2022;14(1):14-24. DOI: 10.55715/jaim.v14i1.333.
22. Golatta M, Pfob A, Busch C, Bruckner T, Alwafai Z, Balleyguier C, et al. The potential of combined shear wave and strain elastography to reduce unnecessary biopsies in breast cancer diagnostics - An international, multicentre trial. Eur J Cancer. 2022;161:1-9. DOI: 10.1016/j.ejca.2021.11.005 PMID: 34879299.
23. Yu Y, Ye X, Yang J, Chen L, Zhang M, He Y, et al. Application of a shear-wave elastography prediction model to distinguish between benign and malignant breast lesions and the adjustment of ultrasound Breast Imaging Reporting and Data System classifications. Clin Radiol. 2022;77(2):e147-e53. DOI: 10.1016/j.crad.2021.10.016 PMID: 34836632.
24. American College of Radiology. ACR BI-RADS Atlas: breast imaging reporting and data system; mammography, ultrasound, magnetic resonance imaging, follow-up and outcome monitoring, data dictionary: ACR, American College of Radiology; 2013.
25. Brkljacic B, Divjak E, Tomasovic-Loncaric C, Tesic V, Ivanac G. Shear-wave sonoelastographic features of invasive lobular breast cancers. Croat Med J. 2016;57(1):42-50. DOI: 10.3325/cmj.2016.57.42 PMID: 26935613.
26. Evans A, Whelehan P, Thomson K, McLean D, Brauer K, Purdie C, et al. Invasive breast cancer: relationship between shear-wave elastographic findings and histologic prognostic factors. Radiology. 2012;263(3):673-7. DOI: 10.1148/radiol.12111317 PMID: 22523322.
27. Evans A, Purdie CA, Jordan L, Macaskill EJ, Flynn J, Vinnicombe S. Stiffness at shear-wave elastography and patient presentation predicts upgrade at surgery following an ultrasound-guided core biopsy diagnosis of ductal carcinoma in situ. Clin Radiol. 2016;71(11):1156-9. DOI: 10.1016/j.crad.2016.07.004 PMID: 27499466.
28. Jin Y, Li F, Du J, Guo Y. Strain elastography features in invasive breast cancer: Relationship between stiffness and pathological factors. Int J Clin Exp Med. 2017;10(9):13290-7.
29. Vinnicombe SJ, Whelehan P, Thomson K, McLean D, Purdie CA, Jordan LB, et al. What are the characteristics of breast cancers misclassified as benign by quantitative ultrasound shear wave elastography? Eur Radiol. 2014;24(4):921-6. DOI: 10.1007/s00330-013-3079-4 PMID: 24326756.
30. Sim YT, Vinnicombe S, Whelehan P, Thomson K, Evans A. Value of shear-wave elastography in the diagnosis of symptomatic invasive lobular breast cancer. Clin Radiol. 2015;70(6):604-9. DOI: 10.1016/j.crad.2015.02.004 PMID: 25770021.
31. Grajo JR, Barr RG. Strain elastography for prediction of breast cancer tumor grades. J Ultrasound Med. 2014;33(1):129-34. DOI: 10.7863/ultra.33.1.129 PMID: 24371107.
32. Christgen M, Steinemann D, Kuhnle E, Langer F, Gluz O, Harbeck N, et al. Lobular breast cancer: Clinical, molecular and morphological characteristics. Pathol Res Pract. 2016;212(7):583-97. DOI: 10.1016/j.prp.2016.05.002 PMID: 27233940.