

Dermatofibrosarcoma Protuberans; Case Report of a Rare Tumor of the Breast

Parisa Hoseinpour¹, Asieh Olfatbakhsh¹, Mahsa Keshavarz -Fathi^{2,3}, Toktam Beheshtian¹, Esmat Alsadat Hashemi¹, Parandis Hoseinpour^{4,*}

¹ Breast Diseases Department, Breast Cancer Research Center, ACECR, Tehran, Iran

² Tehran University of Medical Sciences, Tehran, Iran

³ Cancer Immunology Project (CIP), Universal Scientific Education and Research Network (USERN), Tehran, Iran

⁴ University of Ludwig Maximilian, Munich, Germany

* Corresponding author: Parandis Hoseinpour, University of Ludwig Maximilian, Munich, Germany. E-mail: parandis.hoseinpour@med.uni-muenchen.de

DOI: 10.21859/mci-010111

Submitted: 23 June 2016

Revised: 3 August 2016

Accepted: 22 August 2016

ePublished: 08 September 2016

Keywords:

DFSP

Dermis

Cyst

CD34

Abstract

Introduction: Dermatofibrosarcoma protuberans (DFSP) is an intermediate and slow-growing sarcoma, developing most commonly in the trunk and extremities and rarely in the breast. It may be recurrent, but metastasis is not common. Excisional surgery with enough resection margins decreases the recurrence rate much more.

Case Presentation: An 18-year-old woman presented with posttraumatic bruising of the right axilla near her breast which had been converted to a nodular mass. A well-defined firm mass, fixed to the dermis, palpable with mild tenderness, was present. Ultrasound (US) revealed a cyst with thickened wall, internal echo septa and high vascularity. The findings were suggestive of a complex cyst or infected epidermal inclusion cyst (EIC). Pathological investigation revealed uniform spindle cells in a storiform arrangement. In immunohistochemistry (IHC), tumoral cells showed reactivity for CD34 and the diagnosis of DFSP was made.

Conclusion: Various breast lesions including cysts as well as benign and malignant masses may show similar appearance in imaging studies, which makes clear the crucial role of the pathological and immunohistochemical investigations to confirm a definite diagnosis.

© 2016. Multidisciplinary Cancer Investigation

INTRODUCTION

Dermatofibrosarcoma protuberans (DFSP) is a type of monoclonal soft tissue tumor which appears in the dermis [1]. It is an intermediate and slow-growing sarcoma which tends to local recurrence after resection, but rarely metastases. Frequently, it occurs in adults with age range of 20-50 years; however, it has been reported under and over the mentioned range [2]. Trunk and extremities are the common parts of the body for this tumor [3]. Excisional surgery with resection margins of about 2 cm is undertaken and accompanies with very low recurrence risk [4].

CASE PRESENTATION

An 18-year-old single woman without remarkable medical history presented with posttraumatic bruising of the right axilla near her breast from three months before, which had been converted into a nodular mass at the presentation. In physical examination, a 3 × 2 cm well-defined firm mass, fixed to the dermis, was palpa-

ble with mild tenderness. Ultrasound (US) imaging of the right breast and axilla with 9-14 MHz linear transducer revealed a 31 × 22 × 19 mm cyst with thickened wall, located near the axillary tail, which continued to the dermis (Figure 1). The features, categorized as mildly suspicious of malignancy (BI-RADS 4a), were suggestive of a complex cyst or infected epidermal inclusion cyst (EIC) of the breast. Resection of the nodule with wide local margins was performed. A 50 × 40 × 25 mm creamy soft specimen was removed and assessed. Pathological investigation revealed a neoplastic growth consisting of interlacing fascicles of uniform spindle cells in a storiform pattern with plumped nuclei and inconspicuous nucleoli, showing little variation in size. Peripheral infiltration of the fatty tissue and not the breast tissue was seen (Figure 2). In immunohistochemistry (IHC), tumoral cells showed reactivity for CD34, but not for S100P, and smooth muscle cell actin. The Ki-67 index was 30% in the tumoral cells. The morphology and immunoreactivity staining results were consistent with dermatofibrosarcoma protuberans.

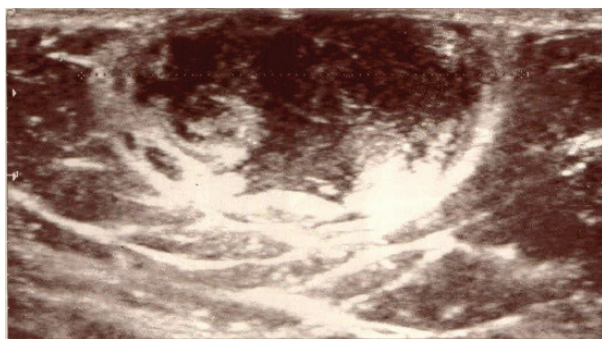


Figure 1: Gray-scale Sonography of the Right Breast and Axilla Showed a Well-Defined $31 \times 22 \times 19$ mm Cyst With Thick Wall, Suggestive of a Complex Cyst or Infected Epidermal Inclusion Cyst

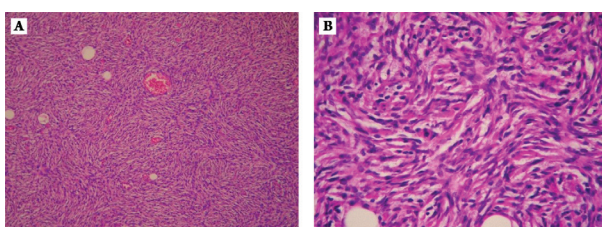


Figure 2: Pathological Appearance Revealed Spindle Cells in a Storiform Pattern, not Including any Breast Tissue. H&E staining; A) $\times 100$, B) $\times 400$.

Dermatofibrosarcoma protuberance (DFSP) was confirmed by positive reaction to CD34 and negative reaction to S100P and smooth muscle cell actin.

DISCUSSION

DFSP is a rare type of mesenchymal neoplasms of the skin, which usually develops in the trunk and extremities. It has been described in 40-50% of cases at the chest and shoulders, in 30-40% of cases at proximal parts of the arms and legs, and in 10-15% at head and neck [5]. Cases with DFSP of the breast have rarely been reported [6]. DFSP accounts for less than 0.1% of all malignant neoplasms and around 1% of all soft tissue sarcomas [7].

In all the races, this tumor could be presented and two times higher incidence rate for blacks rather than whites are recorded [8]. In an epidemiological study in the US, more incidence rate for women [8], and in one review, approximately equal rate for both genders was reported [5]. Some possible events have been discussed as the triggers for DFSP, e.g., trauma has been mentioned in 10-20% of cases. Sites of vaccines, surgery scars, radio-dermatitis, burns, and central venous lines are the less mentioned prone sites to DFSP [5].

Diagnosis of DFSP at first stages is not accomplished easily. Based on the clinical, pathological and immunohistochemical findings, a definite diagnosis is made. Imaging studies are also undertaken either in the case

of atypical clinical findings or in order to determine the location, depth and extent of the invasion, to perform a precise biopsy or resection. Palpability is the other indication for sonography or mammography [9, 10].

The clinical features of this tumor depend on the stage of presentation. Usually, a firm and multinodular tumor fixed to the superficial layers of the dermis appears in blue, red or brown [11]. Often, patients have the tumor steady or slow-growing for a period of time, which varies from months to years. It brings them to the clinic only after increasing growth rate, suffering from pain, or complications like ulceration or hemorrhage of the lesion [12].

US study of a DFSP depicts a subcutaneous oval or round mass adjacent to the skin. It shows either hypo-echogenicity or mixed echogenicity, usually with focal lobulated borders, well-defined or ill-defined margins. Posterior sound enhancement is the other finding in this tumor. Color Doppler sonography may show no blood flow, moderate or less common high vascularity [13-15].

US in the present case showed a well-defined cyst with thick wall, internal echo septa and high vascularity, which was suspicious of malignancy or complicated cysts such as infected EIC or complex cyst. EIC is an epidermal cells growth surrounded by the dermis which could be developed anywhere in the body, often near the hair follicles in the skin, and rarely at the breast skin [16]. EIC could be caused by several triggers including congenital, metaplastic or inflammatory factors, or post-traumatic growth of epidermal elements in the cutaneous and subcutaneous tissues as a result of implantation of the epidermal cells. EIC may be present in non-follicular areas of the skin preceded by trauma [17]. Rupture and inflammation could happen in an EIC as well. US shows oval or round cyst with well-defined margins, though in the case of infection and inflammation ill-defined margins are seen. The echotexture may be cystic or hypo-echoic and heterogeneous. Internal contents of the cyst could be seen as linear echogenic reflectors [18]. Epidermal cysts may have no blood flow at Color Doppler, although infected and inflamed ones show moderate to high vascularity. The most important feature is attachment to the dermis. It may be difficult to differentiate inflammation and superficial malignancies of the breast by imaging [19, 20].

Complex cyst is a lesion with anechoic (cystic) and echogenic (solid) contents at US. It may contain benign or malignant components. Therefore, biopsy is indicated to rule out malignancy [21]. Complex cyst is reported in approximately 5% of the breast US. Higher malignancy risk is associated with thickened walls, internal septa and mixture of solid and cystic contents [22].

As explained above, the diagnosis is made only after biopsy and pathological and immunohistochemical investigations. In this case, pathology and IHC confirmed the lesion as DFSP. The typical appearance of DFSP is a storiform or cartwheel pattern with uniform spin-

dle cells infiltrating into the fatty tissue. The specimen shows positive reactivity for CD34 and vimentin at IHC [23, 24].

Excisional surgery is the choice of treatment for DFSP. Safe and enough resection margins lead to low recurrence rate [25].

ACKNOWLEDGMENTS

The authors would like to express their warm gratitude to the respectable personnel of BCRC, ACECR.

CONFLICTS OF INTEREST

The authors declared that there was no conflict of interests.

REFERENCES

1. Mendenhall WM, Zlotecki RA, Scarborough MT. Dermatofibrosarcoma protuberans. *Cancer*. 2004;101(11):2503-8. DOI: [10.1002/cncr.20678](https://doi.org/10.1002/cncr.20678) PMID: [15503305](https://pubmed.ncbi.nlm.nih.gov/15503305/)
2. Manganoni AM, Pavoni L, Gualdi G, Marocolo D, Chiudinelli M, Sereni E, et al. Dermatofibrosarcoma protuberans in an adolescent: a case report and review of the literature. *J Pediatr Hematol Oncol*. 2013;35(5):383-7. DOI: [10.1097/MPH.0b013e3182843edc](https://doi.org/10.1097/MPH.0b013e3182843edc) PMID: [23528903](https://pubmed.ncbi.nlm.nih.gov/23528903/)
3. Al-Rahbi S, Al-Lawati T, Al-Kharusi S, Thomas S, Al-Harrasi K. Dermatofibrosarcoma Protuberans: A Rare Malignancy of the Breast. *Oman Med J*. 2015;30(5):378-81. DOI: [10.5001/omj.2015.75](https://doi.org/10.5001/omj.2015.75) PMID: [26421120](https://pubmed.ncbi.nlm.nih.gov/26421120/)
4. Woo KJ, Bang SI, Mun GH, Oh KS, Pyon JK, Lim SY. Long-term outcomes of surgical treatment for dermatofibrosarcoma protuberans according to width of gross resection margin. *J Plast Reconstr Aesthet Surg*. 2016;69(3):395-401. DOI: [10.1016/j.bjps.2015.10.027](https://doi.org/10.1016/j.bjps.2015.10.027) PMID: [26646402](https://pubmed.ncbi.nlm.nih.gov/26646402/)
5. Llombart B, Serra-Guillen C, Monteagudo C, Lopez Guerrero JA, Sanmartin O. Dermatofibrosarcoma protuberans: a comprehensive review and update on diagnosis and management. *Semin Diagn Pathol*. 2013;30(1):13-28. DOI: [10.1053/j.semdp.2012.01.002](https://doi.org/10.1053/j.semdp.2012.01.002) PMID: [23327727](https://pubmed.ncbi.nlm.nih.gov/23327727/)
6. Lin JY, Sheen-Chen SM, Hsu W, Huang CC, Ko SF, Eng HL. Dermatofibrosarcoma protuberans of the breast. *Tumori*. 2008;94(6):861-3. PMID: [19267107](https://pubmed.ncbi.nlm.nih.gov/19267107/)
7. Laskin WB. Dermatofibrosarcoma protuberans. *CA Cancer J Clin*. 1992;42(2):116-25. PMID: [1540852](https://pubmed.ncbi.nlm.nih.gov/1540852/)
8. Criscione VD, Weinstock MA. Descriptive epidemiology of dermatofibrosarcoma protuberans in the United States, 1973 to 2002. *J Am Acad Dermatol*. 2007;56(6):968-73. DOI: [10.1016/j.jaad.2006.09.006](https://doi.org/10.1016/j.jaad.2006.09.006) PMID: [17141362](https://pubmed.ncbi.nlm.nih.gov/17141362/)
9. Torreggiani WC, Al-Ismaïl K, Munk PL, Nicolaou S, O'Connell JX, Knowling MA. Dermatofibrosarcoma protuberans: MR imaging features. *AJR Am J Roentgenol*. 2002;178(4):989-93. DOI: [10.2214/ajr.178.4.1780989](https://doi.org/10.2214/ajr.178.4.1780989) PMID: [11906888](https://pubmed.ncbi.nlm.nih.gov/11906888/)
10. Doshi DJ, March DE, Crisi GM, Coughlin BF. Complex Cystic Breast Masses: Diagnostic Approach and Imaging-Pathologic Correlation 1. *Radiographics*. 2007;27(suppl_1):S53-S64.
11. Taylor HB, Helwig EB. Dermatofibrosarcoma protuberans. A study of 115 cases. *Cancer*. 1962;15:717-25. PMID: [13919964](https://pubmed.ncbi.nlm.nih.gov/13919964/)
12. Al Barwani AS, Taif S, Al Mazrouai RA, Al Muzahmi KS, Al-rawi A. Dermatofibrosarcoma Protuberans: Insights into a Rare Soft Tissue Tumor. *J Clin Imaging Sci*. 2016;6:16. DOI: [10.4103/2156-7514.181492](https://doi.org/10.4103/2156-7514.181492) PMID: [27195182](https://pubmed.ncbi.nlm.nih.gov/27195182/)
13. Shin YR, Kim JY, Sung MS, Jung JH. Sonographic findings of dermatofibrosarcoma protuberans with pathologic correlation. *J Ultrasound Med*. 2008;27(2):269-74. PMID: [18204018](https://pubmed.ncbi.nlm.nih.gov/18204018/)
14. Parajuly SS, Peng YL. Sonography of dermatofibrosarcoma protuberans in the skin over breast. *J Med Ultrasound*. 2010;18(3):130-5.
15. Lee RKL. Ultrasound Appearances of Dermatofibrosarcoma Protuberans. *J Med Ultrasound*. 2013;21(1):21-8. DOI: [10.1016/j.jmu.2013.01.009](https://doi.org/10.1016/j.jmu.2013.01.009)
16. Singh M, Maheshwari B, Khurana N, Jain S. Epidermal inclusion cyst in breast: Is it so rare? *J Cytol*. 2012;29(3):169-72. DOI: [10.4103/0970-9371.101165](https://doi.org/10.4103/0970-9371.101165) PMID: [23112456](https://pubmed.ncbi.nlm.nih.gov/23112456/)
17. Kim HS, Cha ES, Kim HH, Yoo JY. Spectrum of sonographic findings in superficial breast masses. *J Ultrasound Med*. 2005;24(5):663-80. PMID: [15840798](https://pubmed.ncbi.nlm.nih.gov/15840798/)
18. Taira N, Aogi K, Ohsumi S, Takashima S, Kawamura S, Nishimura R. Epidermal inclusion cyst of the breast. *Breast Cancer*. 2007;14(4):434-7. PMID: [17986812](https://pubmed.ncbi.nlm.nih.gov/17986812/)
19. Kim HK, Kim SM, Lee SH, Racadio JM, Shin MJ. Subcutaneous epidermal inclusion cysts: ultrasound (US) and MR imaging findings. *Skeletal Radiol*. 2011;40(11):1415-9. DOI: [10.1007/s00256-010-1072-4](https://doi.org/10.1007/s00256-010-1072-4) PMID: [21132291](https://pubmed.ncbi.nlm.nih.gov/21132291/)
20. Giess CS, Raza S, Birdwell RL. Distinguishing breast skin lesions from superficial breast parenchymal lesions: diagnostic criteria, imaging characteristics, and pitfalls. *Radiographics*. 2011;31(7):1959-72. DOI: [10.1148/rg.317115116](https://doi.org/10.1148/rg.317115116) PMID: [22084181](https://pubmed.ncbi.nlm.nih.gov/22084181/)
21. Athanasiou A, Aubert E, Vincent Salomon A, Tardivon A. Complex cystic breast masses in ultrasound examination. *Diagn Interv Imaging*. 2014;95(2):169-79. DOI: [10.1016/j.diii.2013.12.008](https://doi.org/10.1016/j.diii.2013.12.008) PMID: [24433921](https://pubmed.ncbi.nlm.nih.gov/24433921/)
22. Houssami N, Irwig L, Ung O. Review of complex breast cysts: implications for cancer detection and clinical practice. *ANZ J Surg*. 2005;75(12):1080-5. DOI: [10.1111/j.1445-2197.2005.03608.x](https://doi.org/10.1111/j.1445-2197.2005.03608.x) PMID: [16398815](https://pubmed.ncbi.nlm.nih.gov/16398815/)
23. Llombart B, Monteagudo C, Sanmartin O, Lopez-Guerrero JA, Serra-Guillen C, Poveda A, et al. Dermatofibrosarcoma protuberans: a clinicopathological, immunohistochemical, genetic (COL1A1-PDGFB), and therapeutic study of low-grade versus high-grade (fibrosarcomatous) tumors. *J Am Acad Dermatol*. 2011;65(3):564-75. DOI: [10.1016/j.jaad.2010.06.020](https://doi.org/10.1016/j.jaad.2010.06.020) PMID: [21570152](https://pubmed.ncbi.nlm.nih.gov/21570152/)
24. Larbcharoensub N, Kayankarnavee J, Sanpaphant S, Kiranantawat K, Wirojtananugoon C, Sirikulchayanonta V. Clinicopathological features of dermatofibrosarcoma protuberans. *Oncol Lett*. 2016;11(1):661-7. DOI: [10.3892/ol.2015.3966](https://doi.org/10.3892/ol.2015.3966) PMID: [26870263](https://pubmed.ncbi.nlm.nih.gov/26870263/)
25. Kim BJ, Kim H, Jin US, Minn KW, Chang H. Wide Local Excision for Dermatofibrosarcoma Protuberans: A Single-Center Series of 90 Patients. *Biomed Res Int*. 2015;2015:642549. DOI: [10.1155/2015/642549](https://doi.org/10.1155/2015/642549) PMID: [26688814](https://pubmed.ncbi.nlm.nih.gov/26688814/)